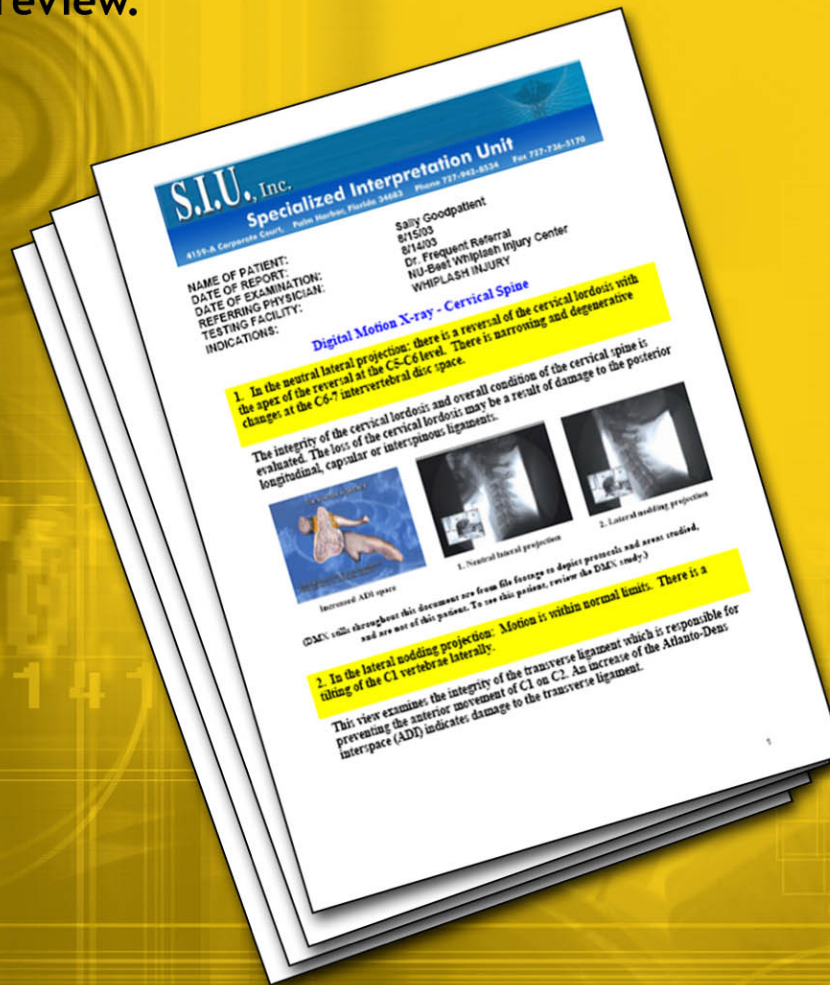


Sample Radiological Report

We are setting a new standard for motion radiological x-rays. A sample of a radiological report is attached for your review.



Seeing is believing.

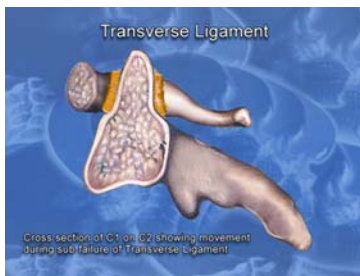
Digital *motion* x-ray®

NAME OF PATIENT: Sally Goodpatient
DATE OF REPORT: 8/15/03
DATE OF EXAMINATION: 8/14/03
REFERRING PHYSICIAN: Dr. Frequent Referral
TESTING FACILITY: NU-Best Whiplash Injury Center
INDICATIONS: WHIPLASH INJURY

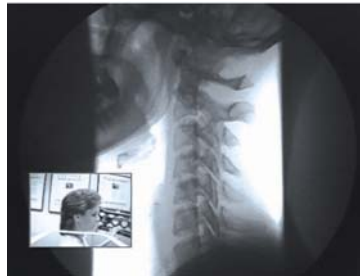Digital Motion X-ray - Cervical Spine

1. In the neutral lateral projection: there is a reversal of the cervical lordosis with the apex of the reversal at the C5-C6 level. There is narrowing and degenerative changes at the C6-7 intervertebral disc space.

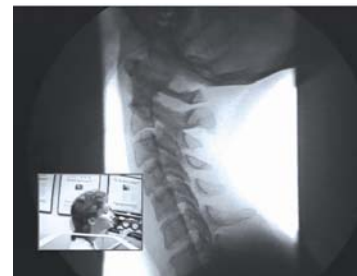The integrity of the cervical lordosis and overall condition of the cervical spine is evaluated. The loss of the cervical lordosis may be a result of damage to the posterior longitudinal, capsular or interspinous ligaments.



Increased ADI space



1. Neutral lateral projection



2. Lateral nodding projection

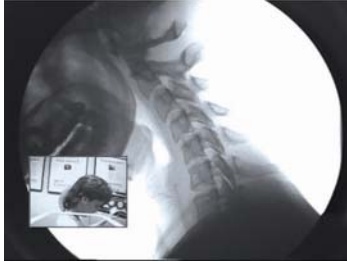(DMX stills throughout this document are from file footage to depict protocols and areas studied, and are not of this patient. To see this patient, review the DMX study.)

2. In the lateral nodding projection: Motion is within normal limits. There is a tilting of the C1 vertebrae laterally.

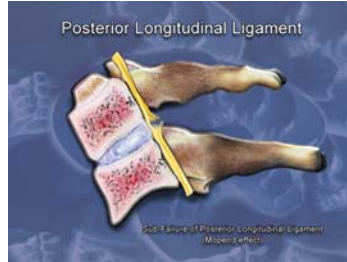
This view examines the integrity of the transverse ligament which is responsible for preventing the anterior movement of C1 on C2. An increase of the Atlanto-Dens interspace (ADI) indicates damage to the transverse ligament.

3. Motion in the neutral lateral projection to full flexion: Shows an anterolisthesis of C5 on C6.

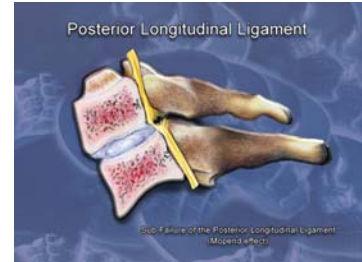
This view examines the integrity of the posterior longitudinal ligament demonstrated by a forward (anterior) movement of one vertebrae over the vertebrae below or by the posterior widening of the intervertebral disc space (increased disc angle).



3. Full flexion projection

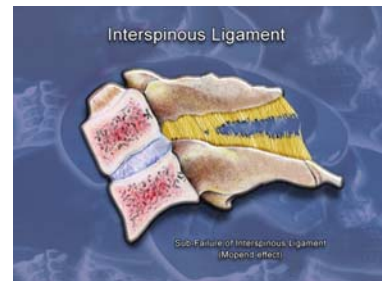


Widening of posterior disc space



Anterolisthesis

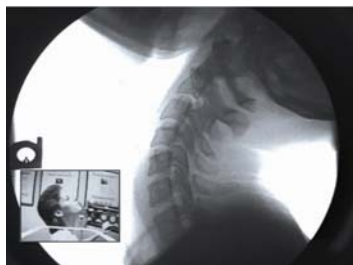The integrity of the interspinous ligament is evaluated in the lateral flexion view. Damage to this ligament results in increased separation of the spinous processes in flexion.



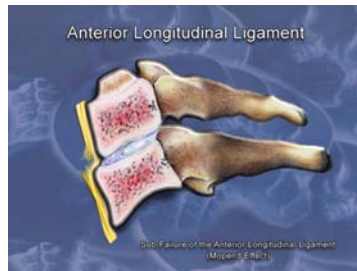
Damaged Interspinous Ligament

4. Motion in the neutral lateral projection to full extension: Shows a retrolisthesis of C2 on C3, C3 on C4, C4 on C5.

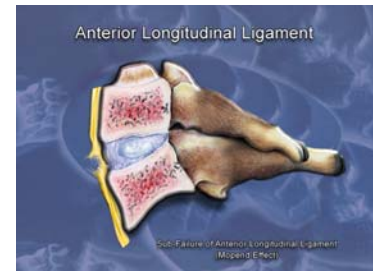
This view examines the integrity of the anterior longitudinal ligament demonstrated by a backward (posterior) movement of one vertebrae over the vertebrae below or by the anterior widening of the intervertebral disc space (increased disc angle).



4. Full Extension



Retrolisthesis



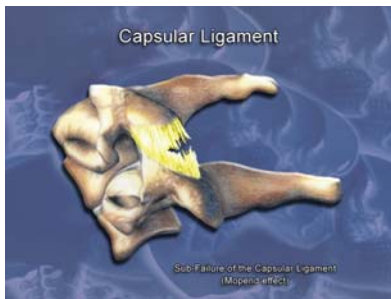
Widening of the anterior disc

5. Motion in the right and left oblique flexion projection: Shows gapping of the facet joints bilaterally at C6-C7, C7-T1.

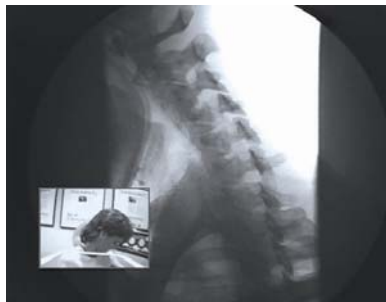This view examines the integrity of the capsular ligaments by observing gapping of the facet joints, located on the posterior cervical spine (C2-C7), there are five capsular ligaments on the right and the left.

6. Motion in the right and left oblique extension projection: Shows intervertebral foraminal encroachment on the right at C4-C5 and on the left at C3-C4.

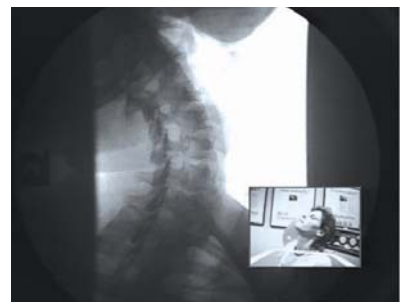This view examines the integrity of the capsular ligament by encroachment into the intervertebral foramen, located on the posterior cervical spine (C2-C7), there are five capsular ligaments on the right and the left.



Capsular ligament damage



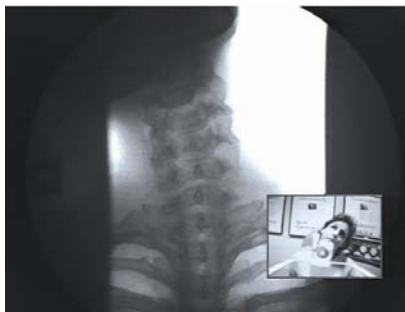5. Right IVF flexion



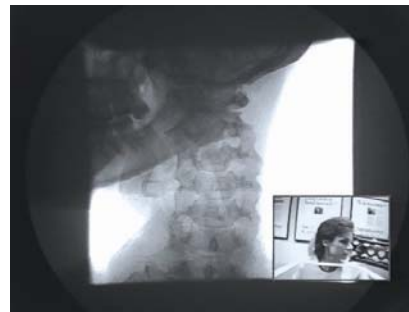6. Left IVF oblique extension

7. Motion in the A-P lateral bending projection: Is restricted bilaterally.

This view allows us to evaluate coupled motion of the spinous processes which examines facet joint integrity.



Left lateral bending



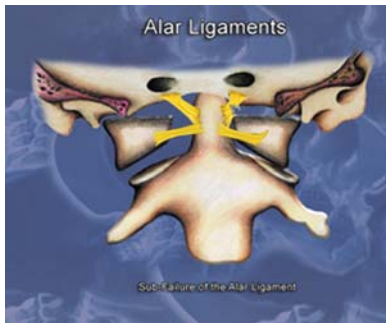
Left rotation

8. Motion in the A-P rotation projection: Is within normal limits.

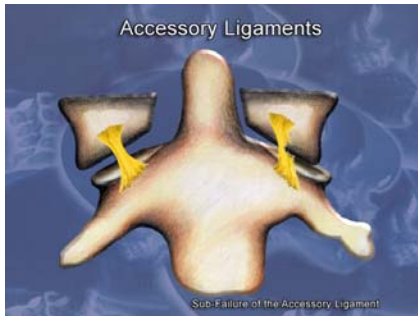
This view examines the rotational range of motion between Occiput-C1-C2. Increased motion indicates damage to the alar and accessory ligaments.

9. Motion in the A-P open mouth lateral bending projection: Shows an abnormal lateral translation of C1 on C2 with an overhang of the lateral mass of C1 bilaterally. Change is noted at the para-odontoid space bilaterally during lateral bending.

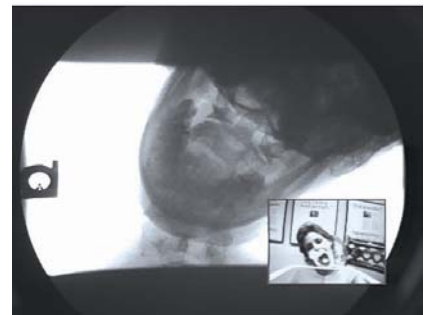
This view examines the integrity of the alar and accessory ligaments either by the lateral overhang of C1 on C2 or by the changes in the para-odontoid spaces.



C1 lateral mass overhang



Change in Para-odontoid space



9. Open mouth right lateral bending

IMPRESSION for patient Sally Goodpatient:

- There is a reversal of the cervical lordosis with the apex of the reversal at C5-C6. Degenerative changes are noted at the C6-C7 intervertebral disc space. A lateral tilting of the C1 vertebrae is present.
- Damage to the posterior longitudinal ligament is indicated by an anterolisthesis at C5-C6.
- Damage to the anterior longitudinal ligament is indicated by a retrolisthesis at C2-C3, C3-C4, C4-C5.
- Damage to the capsular ligament is indicated by gapping of the facet joints at C6-C7, C7-C1 bilaterally and intervertebral foraminal encroachment at C4-C5 right, C3-C4 left.
- Damage to the alar and accessory ligaments is indicated by the overhang of the lateral mass of C1 and changes at the para-odontoid space bilaterally.

John R. Postlethwaite, D.C.
Director of Radiology
Signature electronically applied
JP/bae